

Combined Treatment for Pulmonary Aspergilloma

Erkan Yıldırım, MD; Rasih Yazkan, MD; Koray Dural, MD;
Kadir Koç, MD; Serdar Han, MD; Ünal Sakıncı, MD

Department of Thoracic Surgery, Ankara Numune Education and Research Hospital, Ankara, Turkey

Abstract

Aiming to assess the efficacy of a combined medical-surgical approach in the treatment of pulmonary aspergilloma, the records of 7 patients (4 males, 3 females) who had been admitted to our hospital with this diagnosis between April 2000 and July 2003 were evaluated retrospectively. Four patients had combined medical-surgical treatment, 2 patients had only medical treatment and 1 patient had only surgical treatment. One patient who was on medical therapy died, but this patient also had problems in the application of this treatment.

Based on our experience, we recommend surgical resection combi-

ned with postoperative antifungal therapy for the treatment of pulmonary aspergilloma. We also propose starting initially the medical therapy especially in patients with debility, and reduced pulmonary function. Medical therapy should be the only therapeutic approach if the patients have contraindications for surgery.

Turkish Respiratory Journal, 2004;5:(2):92-96

Keywords: aspergilloma; pulmonary infections; combined medical-surgical treatment

Introduction

Pulmonary aspergillosis results from a colonization or infection of the lung by pathogenic filamentous fungi. The fungus *Aspergillus fumigatus*, is one of the leading etiological agents (1).

Pulmonary aspergilloma may develop in cavitating lung disease of any cause and is most frequently encountered following tuberculosis and sarcoidosis in the upper lobes (1-7,8). Aspergillosis may also occur as a nosocomial infection (9). Invasive pulmonary aspergillosis may develop in hosts with depressed immunity by inhalation of the conidia of the *Aspergillus* or less frequently by hematogenous dissemination of the cutaneous and gastrointestinal infection (10).

In this paper, we aimed to present 7 patients with aspergilloma and discuss the results of a combined medical-surgical approach which seems to be advantageous in pulmonary aspergilloma.

Materials and Methods

The medical records of 7 patients with pulmonary aspergilloma were retrospectively reviewed. The diagnosis of aspergilloma was based on clinical findings, chest X-ray, computed tomography (CT) and laboratory findings. Sputum, bronchial washings and pleural effusion samples were used to isolate the fungi. Treatment was based on a combined medical-surgical therapeutic app-

Corresponding Author: Dr. Erkan Yıldırım
Aşağıöveçler Mah., 79. Sk. 8/3 06460
Dikmen, Ankara, Türkiye
Phone: +90 (312) 310 30 30/2206,
+90 (312) 472 16 29
(0532) 445 39 38
E-mail: erseyda@yahoo.com

Case	Age	Sex	Unilateral	Bilateral
1	62	F	LEFT UPPER LOBE	
2	43	M	-	UPPER LOBES
3	44	M	RIGHT PLEURAL EFFUSION	
4	48	M	-	UPPER LOBES
5	21	M	LEFT LOWER LOBE	
6	35	F	(Cyst cavity) LEFT UPPER LOBE	
7	30	F	RIGHT LOWER LOBE (Cyst Cavity)	

roach in the majority of the patients. Patients with poor pulmonary functions received only medical therapy.

Findings

Findings on 7 cases are summarized in Tables 1-4.

Case	Cough	Hemoptysis	Sputum	Dyspnea	Chest pain	Weight loss	Odynophagia
1	-	-	-	-	+	-	-
2	+	+	+	+	-	-	-
3	-	-	-	-	+	-	-
4	-	+	-	+	-	+	+
5	+	-	+	+	+	-	-
6	+	+	+	-	-	-	-
7	+	+	-	-	+	-	-

Case reports

Case 1: A 62-year-old woman presented with chest pain which had started 1.5 months ago. Chest X-ray (Figure 1a) and CT showed a left apical parenchymal infiltration. *Aspergillus fumigatus* precipitins were positive and the fungus was isolated from sputum and bronchial washings. A left upper lobectomy was performed and itraconazole was administered 2x100 mg/day, orally for 3 months. The postoperative chest X-ray was normal (Figure 1b).

Case 2: A 43-year-old man with ankylosing spondylitis pre-

Specimens	No.
Bronchial aspirate, sputum	4
Percutaneous aspirate	1
Postoperative pathology	2

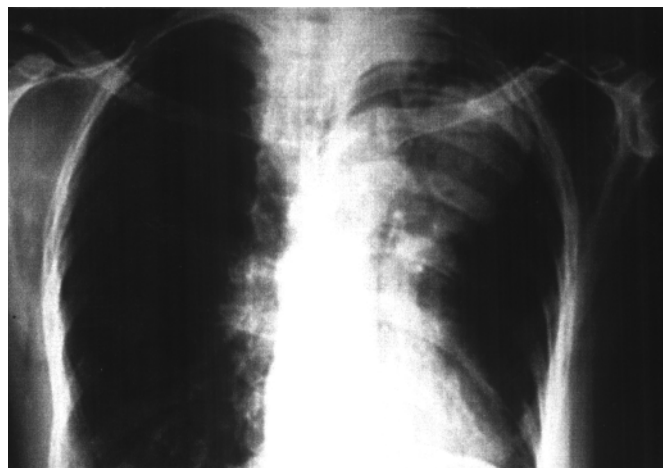


Figure 1a. Preoperative chest X-ray. Note the lesion in the upper region of the left hemithorax.

sented with a 3 months history of cough, hemoptysis, increased sputum production and dyspnea. Hemoptysis was abundant and was observed to be 700 ml on the first day of admission. The patient also had a history of ankylosing spondylitis, diagnosed 20 years prior to admission. Chest X-ray showed fungus balls bilaterally in the apical cavities. A tentative diagnosis of aspergilloma was made and this was confirmed by CT (Figure 2). *Aspergillus fumigatus* hyphae was isolated in the sputum analysis. The patient had poor lung function due to ankylosing spondylitis. Amphotericin B was prescribed and administered intravenously (1.5 mg/kg/day) for a period of 2 months. Unfortunately, the patient was not cooperative and there were difficulties with the administration of the medication. He died 3 months after discharge.

Case 3: A 44-year-old man presented with chest pain. He had a traffic accident one month prior to hospitalization and a right tube thoracostomy was performed as an emergency treatment at another hospital. At admission, the chest X-ray and CT revealed a thickening in the right pleura. A right thoracotomy and decortication were performed. On the postoperative 45th day, a chest X-ray showed a pleural effusion which reached the level of the hilum (Figure 3a). A pleuro-

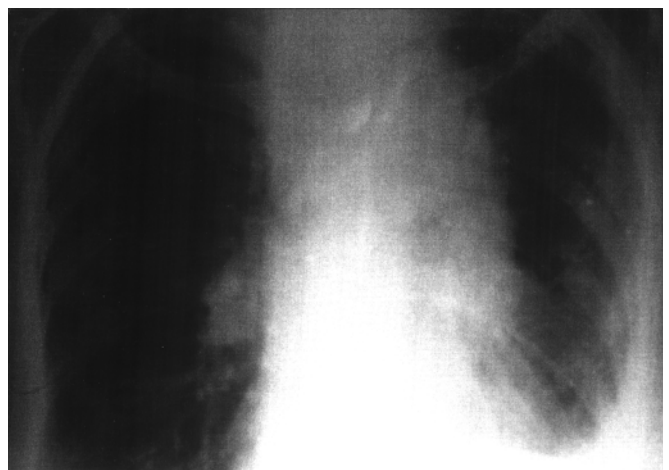


Figure 1b. Postoperative chest X-ray – normal.

Table 4. Treatment approaches, types and dosages

Case	Medical	Surgery	Type of Surgery	Type of Medical Therapy
1	+	+	Left Upper Lobectomy	Itraconazole, 2x100 mg / day, po, 3 mo
2	+	-	-	Amphotericin B, 1.5 mg/ kg / day (uncooperated)
3	+	+	Decortication	Amphotericin B, 70 mg intrapleural; 1.5 mg/kg/ day, systemic, 2 mo
4	+	-	-	Amphotericin B, 1.5 mg/ kg / day, 2 mo
5	-	+	Cystotomy+Capitonnage	-
6	+	+	Left Upper Lobectomy	Amphotericin B, 1.5 mg/ kg / day, 2 mo
7	+	+	Cystotomy+Capitonnage	Amphotericin B, 1.5 mg/ kg / day, 2 mo

can catheter was inserted into the right hemithorax (Figure 3b). *Aspergillus fumigatus* was isolated from the thoracentesis aspirate. Amphotericin B was administered in a dose of 70 mg intrapleurally and at the same time systemically in a dose of 1.5 mg/kg/day for 2 months. Recovery was uneventful.

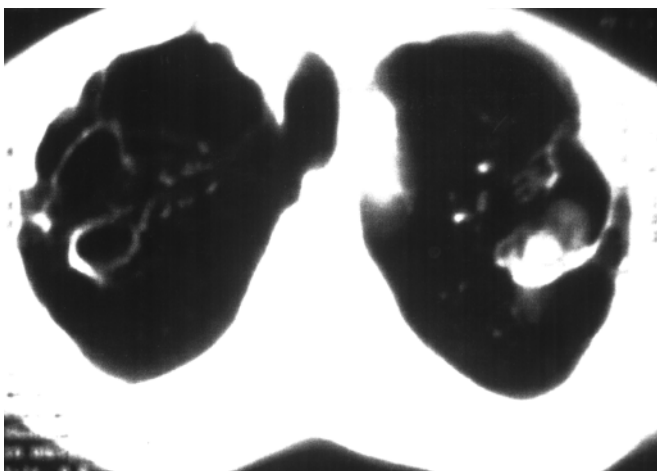


Figure 2. Preoperative computerized tomography showing bilateral fungus balls in the cavities in a patient with ankylosing spondylitis.

Case 4: A 48-year-old man presented with complaints of a weight loss of 12 kg, hemoptysis, dyspnea and odynophagia in the past 1 month. Chest X-ray and CT showed bilateral fungus balls in the apical aspergilloma cavities. In addition, the patient had poor pulmonary function. Surgical intervention was not performed and only amphotericin B, 1.5 mg/kg/day for a period of 2 months was given intravenously. He was uneventful at the end of the 2-month course of medication. The patient was advised to be followed up by a specialist in chest diseases.

Case 5: A 21-year-old man presented with dyspnea, chest pain, cough and sputum production. Chest X-ray showed a ruptured cyst hydatid in the left lung. Following left thoracotomy, cystotomy and capitonnage were performed. On follow-up 3 months later, a persistent cavity was detected in the chest X-ray (Figure 4a) and CT images. The left thoracotomy was repeated and some debris/clots were identified in the cavity. These were evacuated totally and then the capitonnage was performed as usual. Postoperative pathohistological diagnosis was intracavitary aspergilloma. The postoperative course was uneventful. A chest X-ray obtained 2 months after the second operation was normal (Figure 4b). Medical therapy could not be given due to the psychiatric problems of the patient.

Case 6: A 35-year-old woman presented with cough, hemoptysis and sputum production occurring in the past 3 months. Chest X-ray and CT showed a left apical parenchymal infiltration. *Aspergillus fumigatus* precipitins were positive in the sputum and hyphae were isolated from the sputum analysis. A left upper lobectomy was performed and amphotericin B 1.5 mg/kg/day was administered systemically for 2 months. She was uneventful on her control at postoperative 6th months.

Case 7: A 30-year-old woman presented with symptoms of productive cough, hemoptysis and chest pain. Twenty years ago she had received albendazole as a medical treatment for pulmonary hydatid cyst. On physical examination, there were no pathologic findings. Preoperative chest X-ray and computerized tomography (CT) showed a cystic lesion, 34x23 mm in diameter, in the right lower lobe. A right thoracotomy was performed, which showed a cystic lesion in the lower lobe. Cystotomy and capitonnage were successfully performed. Postoperative pathohistological diagnosis was intracavitary aspergilloma. The postoperative course was uneventful. Amp-

erative course was uneventful. A chest X-ray obtained 2 months after the second operation was normal (Figure 4b). Medical therapy could not be given due to the psychiatric problems of the patient.

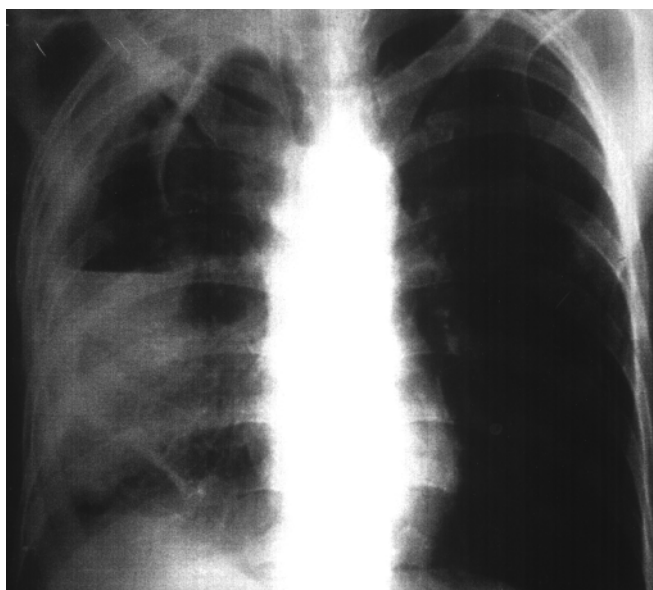


Figure 3a. Chest X-ray showing pleural effusion reaching the hilum level.

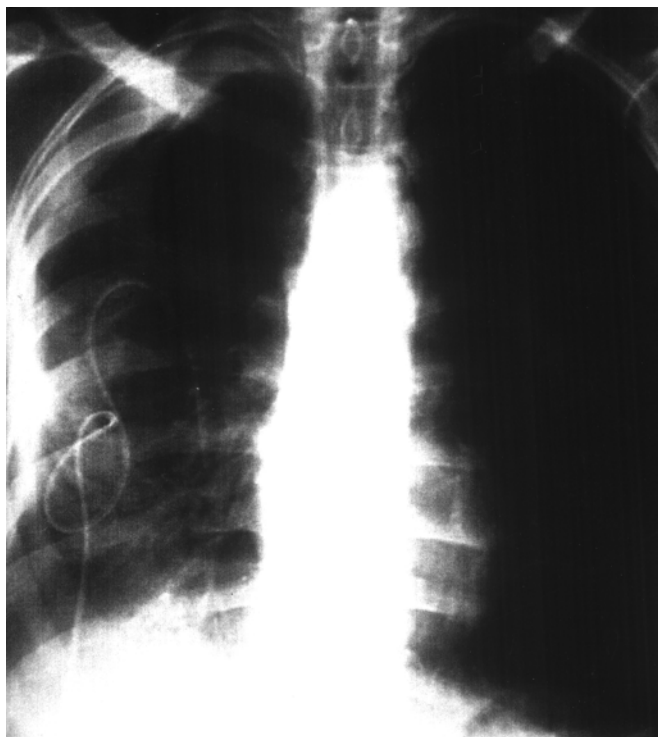


Figure 3b. Follow-up chest X-ray. Note the pleurocan catheter inserted into the right hemithorax to drain the effusion.

hothericin B, 1.5 mg/kg/day, was administered systemically for 2 months. Control radiographies were all unremarkable.

Discussion

The filamentous aspergillus species invade the body through the respiratory tract and colonize in the bronchi and lungs (1,9). Aspergilloma formation is an uncommon event in cavitating lung disease (1-11,12,13). Latent tuberculosis, sarcoidosis, bronchiectasis, bronchial cysts, chronic abscess, cavity of carcinoma, rheumatoid arthritis, intrapulmonary sequestration and histoplasmosis are some of the underlying conditions which facilitate infestation by the fungi (14).

Invasive pulmonary aspergillosis, allergic bronchopulmonary

aspergillosis and mycetoma with a typical appearance of a "fungus ball" in the chest X-ray constitute the three principal categories of aspergillosis disease (1,6,15,16). Aspergillus organisms can be isolated in bronchial aspirates, sputum, and bronchoalveolar lavage fluid (1,2,4).

In five of our patients, presence of a fungus ball was identified in the radiographic images. Additionally, the diagnosis was supported by the analyses of sputum, bronchial washing and empyema in four of these patients. In one patient, probably due to superinfection (9,17), the aspergillus hyphae were demonstrated in the pleural effusion, a finding which might have been due to aspergillus empyema.

Pulmonary aspergilloma shows a predilection in males. Average age at presentation is reported as 65 years. In the present series there were 4 males and 3 females and mean age was 40 years.

Most patients with aspergilloma are reported to be asymptomatic. The most common symptoms on admission were cough and a sputum tinged with blood. Other reported symptoms at presentation were hemoptysis, dyspnea, fever, and general fatigue (1-3,6). In our patients, the most common symptoms were cough, hemoptysis, chest pain, and dyspnea. Weight loss and odynophagia were rarer symptoms.

In the literature, the right upper lobe is defined to be the most common site for location of the aspergillosis, followed by the left upper lobe in frequency (1,6). In the present series, lesions were more frequently detected unilaterally in 5 of the cases and bilaterally in 2. In the unilateral group, aspergilloma was located mainly in the left upper lobe whereas in the bilateral group, it was located in both upper lobes.

The preexisting lesions have also been reviewed in the literature (18). Those detected in the current study were poor pulmonary function due to emphysematous parenchyma, cyst hydatid cavity, and empyema.

Surgical and medical therapeutic approaches are recommended in the treatment of pulmonary aspergillosis. Itraconazole and other antifungal drugs have been used orally, and amphotericin B has been administered both locally into the cavity

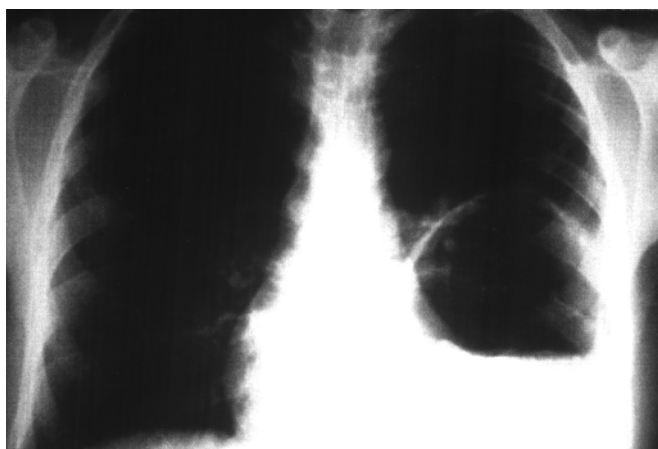


Figure 4a. Chest X-ray showing a persistent cavity determined 3 months after cystotomy + capitonnage.

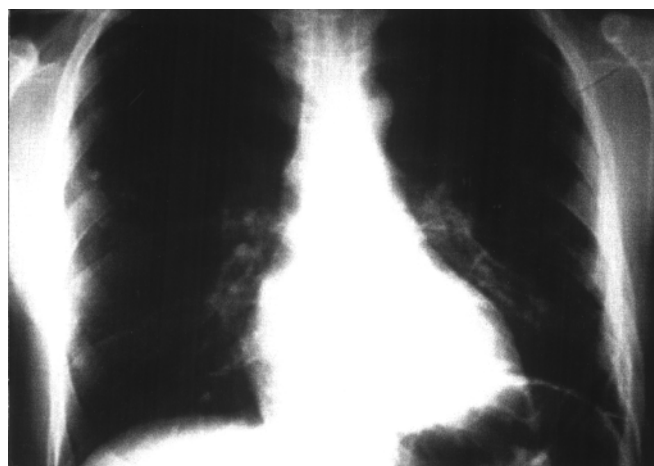


Figure 4b. Control chest X-ray obtained 2 months after the second operation.

and intravenously (1-3). At times, surgical treatment may be contraindicated because of limited respiratory reserve or other problems. In these situations, medical therapy only by systemic antifungal therapy and endobronchial or intracavitary instillation of antifungal agents have been attempted; with limited success. One of the disadvantages of medical therapy has been the necessity for repeated treatment (19). Surgical resection of aspergilloma is associated with a significant morbidity and mortality (2,4,5). Jewkes et al. reported a 7% postoperative mortality rate. Major complications such as bronchopleural fistula and hemorrhage have been reported to develop in 15%-20% of the patients (2). In our group, the early postoperative course was uneventful and there were no patients with major complications. There was one death, which occurred in a patient in the non-surgical therapy group. Although our patient experience is relatively small, we found that a combined medical-surgical approach was well tolerated by the patients without any major complications in the follow-up. We propose that medical therapy be instituted also patients in whom surgical intervention was successfully performed, and in patients who have contraindications to surgery.

References

1. Kawamura S, Maesaki S, Tomono K, et al. Clinical evaluation of 61 patients with pulmonary aspergilloma. *Internal Medicine* 2000;39(3):209-12.
2. Jackson M, Flower CDR, Shneerson J M. Treatment of symptomatic pulmonary aspergillomas with intracavitary instillation of amphotericin B through an indwelling catheter. *Thorax* 1993;48:928-30.
3. Lee KS, Kim HT, Choe KO. Treatment of hemoptysis in patients with cavitary aspergilloma of the lung: Value of percutaneous instillation of amphotericin B. *AJR* 1993;161:727-31.
4. Giron JM, Poey CG, Fajadet PP, et al. Inoperable Pulmonary Aspergilloma: Percutaneous CT-guided injection with Glycerin and Amphotericin B Paste in 15 Cases. *Radiology* 1993;188:825-27.
5. Aderaye G, Jajaw A. Bilateral pulmonary aspergilloma: Case report. *East African Medical Journal* 1996;73(7):487-88.
6. Chintapalli K, Sheth NK, Goodman L. Unusual "cavity in cavity" appearance of pulmonary aspergilloma. *The Journal Of Computed Tomography* 1988;12:64-7.
7. Mcgregor HD, Papasian JC, Pierce PD. Aspergilloma within cavitating pulmonary adenocarcinoma. *Am J Clin Pathol* 1989;91:100-3.
8. Türker H, Karakurt Z, Akın H, et al. Pulmonary Aspergilloma in a Turkish Hospital Population. *Turkish Respiratory Journal* 2002;3(1):7-14.
9. Yenerel NM, Kalayoğlu-Beşışık S, Sanwara I, et al. Yoğun Kemoterapi Ünitesinde Eşzamanda Ortaya Çıkan Dört İnvazif Pulmoner Aspergilloz Olgusu. *Toraks Dergisi* 2000;1(2):41-44.
10. Uçan ES, Sevinç C, Kurtar N, et al. Ülseratif Kolitit Bronşiektazi, Bronşiyolitit Obliterans ve İnvazif Pulmoner Aspergilloz ile Seyreden İlerleyici Akciğer Tutulumu. *Toraks Dergisi* 2001; 2(1):44-49.
11. Okana H, Tachibana A, Nagayama M, et al. Productive aspergilloma on the inner wall of a cavity. *Nihon Kyobu Shikkan Gakkai Zasshi* 1989;27(7):761-7.
12. Doyle L. An early report of growth of an aspergillus species on the wall of a lung cavity. *Thorax* 1989;44:66-7.
13. Hendrix WC, Arruda LK, Platts-Mills TAE, et al. Aspergillus epidural abscess and cord compression in a patient with aspergilloma and empyema. *Am Rev Respir Dis* 1992;145:1483-6.
14. Öztürk E, Tümer Ö, Hazar A, et al. A Case of Inactive Tuberculosis Coexisting with Adenocarcinoma and Aspergilloma. *Turkish Respiratory Journal* 2003;4(3):147-149.
15. Ulaşan NG, Dural K, Yildirim E, et al. An intracavitary aspergilloma after echinococcal cystectomy. *J Cardiovasc Surg (Torino)*. 2003 Apr;44(2):289-90.
16. H. Pabuççuoğlu U, Özkara E, Ceylan E, et al. Oxalosis Around a Pulmonary Fungus Ball (Aspergilloma). *Turkish Respiratory Journal* 2003;4(1):21-24.
17. Rzepecki W, Wojcik B. Surgical treatment of pleural empyema superinfected by Aspergillus. *Pol Med J*. 1969;8(6):1312-9.
18. Stamatis G, Greschuchna D. Surgery for pulmonary aspergilloma and pleural aspergillitis. *Thorac Cardiovasc Surg* 1988 Dec; 36(6):356-60.
19. Munk PL, Vellet AD, Rankin RN, et al. Intracavitary aspergilloma: Transthoracic percutaneous injection of Amphotericin Gelatin Solution. *Radiology* 1993;188:821-23.